



**PATIENT**

Sophie Robe

**PRESENTING CLINICAL SIGNS**

History: Presented for dental procedure. Arrhythmia noted with pulse deficits on exam. Otherwise, is asymptomatic. HR- 110-120bpm

**SPECIES**

Canine

**RADIOGRAPHIC FINDINGS** \*NOTE: Images submitted for supplemental cardiac information only.  
Normal cardiac silhouette. No obvious evidence of CHF.

**BREED**

Boxer

**ELECTROCARDIOGRAPHIC FINDINGS** \*Note: Single lead ECGs are evaluated as a rhythm strip.  
Morphology/MEA cannot be definitively commented on.

A single lead ECG is available; 25mm/s, 5mm/mV. The underlying rhythm is sinus in origin. Mm marks are difficult to visualize; however, and average heart rate of 160bpm is suspected. P for every QRS complex and vice versa. The P and QRS morphologies are positive. Frequent VPCs are identified with bigeminy. A single tight couplet is appreciated. No supraventricular premature beats, pauses or other dysrhythmias observed.

**SEX**

Female Spayed

ECG diagnosis: Normal sinus rhythm with ventricular bigeminy and a single ventricular couplet.

**AGE**

9 years

**ECHOCARDIOGRAM FINDINGS**

2D, m-mode, color flow and doppler imaging is available. The mitral valve appears normal in form and function, with no obvious prolapse into the left atrial lumen. Trace central MR seen. Normal left atrial dimension. Normal LV diameter with adequate myocardial function. Normal LV wall thickness. The tricuspid valve appears normal in form and function. No overt evidence of pulmonary arterial hypertension or right heart compensation, however right heart is prominent. Trace tricuspid regurgitation. Normal velocity. The aortic valve is normal in morphology and mobility. No subvalvular ridge present, mildly increased velocity. No aortic insufficiency. Normal pulmonic valve with no pulmonic insufficiency seen. No pericardial or pleural effusion noted. No obvious cardiac tumors. Irregular rhythm noted throughout the examination.

**WEIGHT**

52lbs

**INTERPRETED BY**

Maggie Machen Lamy,  
DVM, DACVIM  
(Cardiology)

**CARDIAC CHART**

**IMAGING PERFORMED BY**

Sarah Pender, CVT

CANINE CARDIAC PARAMETERS	MR VMAX (m/s)	TR VMAX (m/s)	LA/AO (Boon method)	LA/AO (Heart Base; Swe)	FS (%)	EF (%)	EPSS (cm)
NORMAL PARAMETER	4.5-5.5	<2.7	1.3	<1.6	28-40	40-100	<0.6
PATIENT	5.0	2.4	NM	1.35	28	55	0.6
CANINE CARDIAC PARAMETERS	HR (BPM)	AV VMAX (m/s)	PV MAX (m/s)	BODY WEIGHT (kg)	LA 2D short axis Base view (cm)	LVIDd Avg; 2D and m-mode short axis (cm)	LVIDs Avg; 2D and m-mode short axis (cm)
NORMAL PARAMETER	50-100	0.7-1.7	0.7-1.6	BELOW	BELOW	BELOW	BELOW
PATIENT	130	2.0	1.5	23.6	2.7	3.7	2.7
*Normal chamber parameters expressed as a mean value (SD)				3	1.27 (5.3)	2.46 (2.46)	1.36 (5.5)
<b>BODY WEIGHT DEPENDENT PARAMETERS</b>				5	1.40 (4.5)	2.74 (5.2)	1.60 (4.7)
<i>*Note: All measurements based upon multi-modal images and methods. An average value is reported.</i>				10	1.50 (3.8)	3.27 (3.5)	2.06 (3.1)
				15	1.83 (2.0)	3.71 (2.4)	2.43 (2.1)
				20	2.02 (1.9)	4.14 (2.2)	2.80 (2.0)
				25	2.18 (2.4)	4.48 (2.9)	3.10 (2.5)
				30	2.33 (3.3)	4.83 (3.9)	3.39 (3.4)
				35	2.48 (4.3)	5.17 (5.0)	3.69 (4.5)

Adapted from June Boon, Veterinary Echocardiography, 1998  
Rishniw M and Hollis NE, J Vet Intern Med 2000; 14:429-435  
Hansson et al, Vet Rad and Ultrasound 2002

**HOSPITAL NAME**

SVS Imaging QC

**REFERRING VET**

Bright Eyese & Bushy  
Tails VH

**INVOICE**

29719

**DATE**

3/20/23

**PATIENT**

Bonagura et al. Echocardiography: principles of interpretation, Vet Clin North Am 15:1177, 1995	40	2.62 (5.2)	5.48 (6.1)	3.96 (5.4)
	50	2.88 (7.1)	6.07 (8.3)	4.46 (7.4)

Sophie Robe

**SPECIES**

Canine

**BREED**

Boxer

**SEX**

Female Spayed

**AGE**

9 years

**WEIGHT**

52lbs

**INTERPRETED BY**Maggie Machen Lamy,  
DVM, DACVIM  
(Cardiology)**IMAGING PERFORMED BY**

Sarah Pender, CVT

**HOSPITAL NAME**

SVS Imaging QC

**REFERRING VET**Bright Eyes & Bushy  
Tails VH**INVOICE**

29719

**DATE**

3/20/23

**INTERPRETATION OF THE FINDINGS & FURTHER RECOMMENDATIONS**

The cardiac structure and function are essentially normal in this patient. There is mild right heart prominence in some views, however this is angle dependent and may be a normal variant. The left heart dimensions are normal, and the systolic function considered adequate. Trace MR and TR is noted and may suggest early valve disease and monitoring is recommended. No other valvular insufficiencies were noted and no structural issues identified.

Frequent ventricular premature contractions were however confirmed as the cause of the noted arrhythmia. Ventricular bigeminy is present with a single couplet. VPCs are generated from abnormal conductive or fibrotic tissue in the ventricles of the heart muscle, and even frequent single VPCs will often cause no clinical signs in dogs. When sustained however, ventricular tachycardia can lead to symptoms such as lethargy and collapse.

VPCs are a very non-specific finding. They can be primary in origin (such as ARVC), be secondary to significant cardiac disease (not present in this study) or be extra-cardiac in origin; i.e., due to pain, stress, inflammation, cancer, GI disease, DIC/sepsis, etc. In a 9yo Boxer, there is high suspicion for ARVC (most common age of onset 6-8yo, often asymptomatic). ARVC can occur with or without systolic dysfunction and structural issues, however this should be monitored going forward for any progressive issues. It is always reasonable to rule out other differentials for VPCs (AUS, tick titers, troponin, etc.) however suspicion is low given the signalment of the patient. Unfortunately there is always an elevated risk for collapse and sudden death in any arrhythmic patient, and even on medications this risk unfortunately still persists. ARVC carries a HIGHLY variable prognosis, with some dogs able to remain asymptomatic for extended periods of time, and others developing exercise intolerance, syncopal episode, and refractory arrhythmias/sudden death imminently.

Based strictly upon the amount of arrhythmia present on the available ECG in this asymptomatic dog, anti-arrhythmic therapy is indicated. This is based upon not only the frequency of VPCs, but the finding of a tight couplet. Once sotalol is on board, an extended time 6 lead ECG and/or **holter monitor** is a reasonable next step to allow monitoring of the rhythm throughout 24 hours of a normal day to ensure good rhythm control.

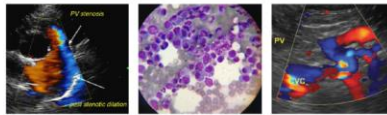
Fish oil supplementation is recommended for dogs with arrhythmias (1000mg of omega 3 and 6 once to twice daily as tolerated).

Anesthetic risk is considered moderate. Avoid ketamine, telazol, Dexdomitor (or other alpha-2 agonists) and acepromazine. Recommend having lidocaine CRI available for use in the event of worsening ventricular arrhythmias under anesthesia (CRI 50–75mcg/kg/min).

Monitor at home for collapse, exercise intolerance, and/or lethargy. Anesthesia is not recommended until good arrhythmic control is achieved. Lifelong mild to moderate activity restriction is advised.

**IMAGING PERFORMED BY**

svsmobileimaging.com 309-737-3070



**PATIENT**

Sophie Robe

**PLAN**

Institute sotalol 1-2mg/kg PO q12h. Recheck ECG in 1-2 weeks to assess response (goal is significant reduction in ectopy without a significant change in underlying sinus rate). Consider holter at this time if desired.

**SPECIES**

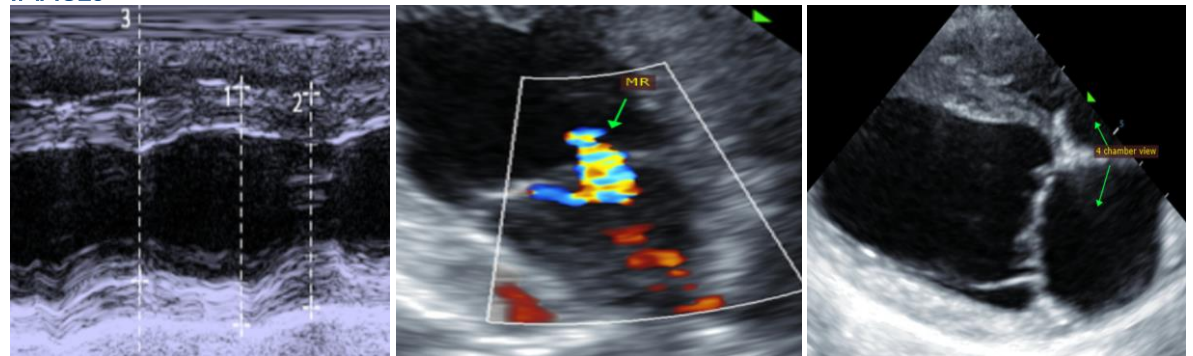
Canine

Recheck ECG and echocardiogram is recommended in 6 months to determine progression/control, sooner if any development of associated clinical signs.

**BREED**

Boxer

**IMAGES**



**SEX**

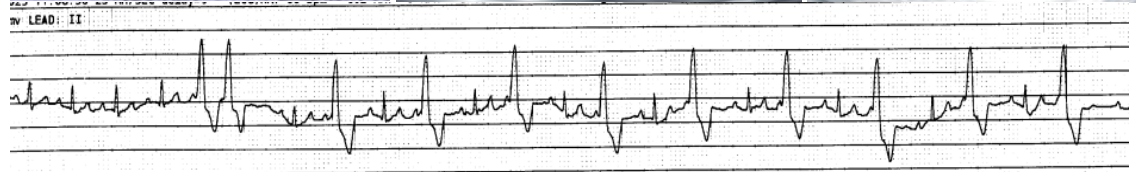
Female Spayed

**AGE**

9 years

**WEIGHT**

52lbs



**INTERPRETED BY**

Maggie Machen Lamy, DVM, DACVIM (Cardiology)

The information and recommendations provided are based on the images presented by the referring veterinarian. No evaluation can be communicated regarding pathology that was not visible in the image/video clips provided.

Thank you for this referral. If the clinical or image interpretation does not parallel your findings or if I can be of any further assistance, please contact me.

**IMAGING PERFORMED BY**

Sarah Pender, CVT

Maggie Machen Lamy, DVM  
Diplomate of the American College of Veterinary Internal Medicine (Cardiology)  
info@sonopath.com

**HOSPITAL NAME**

SVS Imaging QC

**REFERRING VET**

Bright Eyese & Bushy Tails VH

**INVOICE**

29719

**DATE**

3/20/23